Ultrasound for obstetric neuraxial anesthetic procedures: Practical and useful?

Central neuraxial blocks (CNBs), namely spinals and epidurals, are routine procedures in obstetric anesthetic practice. According to the Third National Audit Project,[1] approximately 325,000 spinals, 293,000 epidurals and 42,000 combined spinal-epidural were performed annually in the United Kingdom (UK). Obstetric spinals and epidurals made up 45% of all neuraxial procedures in the census phase of the national audit and approximately 25% of laboring women in the UK received epidural analgesia. Our recent audit (unpublished data) demonstrated that procedural failure was responsible for 50% cases that needed general anesthesia for caesarean sections. Failure rate for epidural analgesia can be as high as 20%.[2]

CHALLENGES OF LANDMARK TECHNIQUE

Weight gain, pelvic rotation, hyperlordosis, tissue edema, and suboptimal positioning predispose difficulty in the performance of neuraxial block during pregnancy. Traditionally, an imaginary horizontal line joining the two superior parts of the posterior iliac crests (Tuffier's line, Jacoby's line or the intercristal line) is used as an anatomical landmark, as it is believed to pass through the L_4 vertebral body[3] for the estimation of vertebral levels for CNBs. During pregnancy, this landmark can be potentially positioned higher than the L_4 or L_5 vertebral levels.[4] It is of utmost importance to identify the vertebral levels correctly to avoid needle trauma to the spinal cord, which usually ends at L_{1-2} level in adults, but this can have significant variability from the lower half of T_{12} to the upper half of L_3 vertebra.[5] Major permanent complications, although rare, continue to be reported when the vertebral level is misidentified.[1,6] This could have potential medico-legal implications to the anesthesiologist. The level at which the procedure is performed also affects the level of the neuraxial blockade.[7]

This high variability of the landmark we traditionally use for CNBs has unsurprisingly meant that we, as anesthesiologists, are extremely poor at identifying the correct and therefore, safe vertebral level. Our data[8] demonstrated an accuracy rate of only 45.4% (n = 91) and that was reduced further to 39.2% if we consider obstetric patients only (n = 51). Worryingly, 10.2% of CNBs were performed at or above the L_2 vertebra. These accuracy rates are like to be overestimation because of the small number and the limitations of retrospective ultrasound (US) scanning. Inaccuracy in identifying correct landmarks was highlighted by Broadbent *et al.*[9] who utilized magnetic resonance imaging (MRI) to confirm the position of their estimated vertebral level by landmark technique. The space was correctly identified in only 29% of cases, and the error made by 51% showed a tendency to think the interspinous space they identified was lower than it actually was. Srinivasan *et al.*[10] also demonstrated inaccuracy of the landmark technique for patients undergoing elective lower segment caesarean section (LSCS). They compared two groups: Group A performed spinal at or above the level when the Tuffier's line intersected a space, and Group B performed below when this line intersected a spinous process. The actual space performed was then identified by a blinded investigator using US. They found that 45.5% of those in Group A would be performing the procedure at or above L_{2-3} intervertebral space.

USEFULNESS OF ULTRASOUND

Estimation of intervertebral space by US is more accurate than by landmark technique as it allows the operator to count the number of spinous processes or laminae upward from the sacrum.[11] Lee *et al.*[12] found that in >40% of pregnant population the level identified clinically was at least one space above that identified by US. It is also interesting that different sonoanatomy of the spine had been reported in

Access this article online

Quick Response Code:

Website: www.joacc.com

DOI: 10.4103/2249-4472.165130

Cite this article as: Lie J, Patel S. Ultrasound for obstetric neuraxial anesthetic procedures: Practical and useful?. J Obstet Anaesth Crit Care 2015;5:49-53.

those with previous unintentional postdural puncture headache.[13] Evidence suggests that US imaging of the spine by an experienced operator can achieve an accuracy rate of >90% (compare to 32% for novices).[14] In a randomized control study in nonobstetric population with difficult surface anatomical landmarks undergoing spinal anesthesia first attempt success was twice in US group.[15] The study population included were patients with body mass index (BMI) more than 35 kg/m² and poorly palpable spinous processes; moderate to severe lumbar scoliosis; or previous lumbar spine surgery. Similar anatomical landmarks are not uncommon in parturients.

The efficacy and safety records of using US for catheterization of epidural space were reviewed by Shaikh *et al.*[16] and more recently by Perlas *et al.*[17] Both meta-analysis showed beneficial outcomes with US-facilitated spinal or epidural techniques. The numbers for failure rate, incidence of traumatic procedures, number of attempts and needle redirections were all reduced with the use of US. Perlas *et al.*[17] suggested that US not only complements the landmark palpation but it has potential to improve safety of neuraxial anesthetic techniques. Use of US for epidural procedure has been recommended by National Institute for Health and Clinical Excellence since 2008.[18]

Several factors can cause procedural difficulty during spinal or epidural technique including obesity, spinal deformity, and previous spinal surgery. Ultrasonography can be useful to identify midline, to predict the depth of epidural space and to direct the insertion needle. It can demonstrate running course of spinal canal (e.g. in scoliosis) and the location of any surgical metals in the back. In our audit of failed procedural neuraxial technique, obesity was the most common cause. Our audit of high risk obstetric outpatient clinic showed 42% and 23% referred cases were morbidly obese, and with lumbar musculoskeletal problems respectively.[19] Some of our colleagues have started using US in high risk obstetric antenatal clinics for anticipated difficult cases for neuraxial anesthesia or analgesia. In anticipated difficult cases, ultrasonography can be performed; images can be stored or printed for records. It facilitates advanced discussion with women with regards to potential difficulties for neuraxial techniques.

In obese pregnant patients, ultrasonography can be useful to reduce number of epidural attempts and the rate of epidural catheter replacements[20] and may prevent accidental dural puncture. The first attempt success rates under US guidance were 92% in comparison to 44% using a conventional technique in obese parturients undergoing spinal anesthesia for elective LSCS.[21] In addition, number of attempts, and duration of procedure were significantly less with the use of US in obese women. In a small study[22] of obese (BMI >35 kg/m²), US measured depth of epidural space correlated with the depth measure by MRI (70.1 [standard deviation (SD) 13.1] vs. 72.4 [SD 12.8]; $P = 0.29$). However, US imaging was difficult in women with BMI >45 kg/m². Increased number of reflective interfaces, exaggerated attenuation, and phase aberration (uneven speed of sound waves through irregularly shaped adipose layers) are some of the causes for technical difficulty with the use of US in obese women.[23] Technological advancements are necessary for optimal use of US in women with morbid and super obesity.

TECHNIQUE AND TRAINING

Below is a brief step-by-step guide on scanning the lumbar spines using US with the patient in sitting position. It is possible to perform the scan with the patient in the lateral decubitus position, but the spine may not be in a straight line making it more difficult.

- Step 1: Paramedian sagittal approach at the lower back to identify the sacrum and the desired level of the spine. Orient the probe toward midline to achieve "saw-tooth" appearance indicating lamina and interlaminar space [Figure 1].
- Step 2: Count up the levels from sacrum (L_5S_1) to your desired level.
- Step 3: Rotate probe by 90° at your desired vertebra (e.g., L_3 for L_{3-4} space). Transverse view at spinous process shows "tower" sign indicating the spinous process [Figure 2].
- Step 4: Slowly move probe caudally into desired intervertebral space (e.g., L_{3-4}). "tower" sign will disappear as the probe is moved into space either caudally or cephalad. A "flying bat" sign will then emerge [Figure 3].
- Step 5: Mark midline and level on side of probe using surgical marker, followed by an indentation on the skin using a needle cap to keep insertion point visible after cleaning with antiseptic solution.

Currently, there is no US probe portable and sophisticated enough to allow real time performance of spinal or epidural. Therefore, the gap between time of the scan and the actual performance of the procedure should be kept as minimal as possible to minimize alterations of the identified intervertebral space. In terms of the number of scans required to be competent in achieving >90% accuracy in intervertebral level for CNBs, Halpern *et al.*[14] showed that a novice would require 23-39 US scans to reach that target.

There is certainly a steep learning curve.[24] However, training by attending workshops may improve its wider use and clinical applications. One of the authors (JL) has established a training

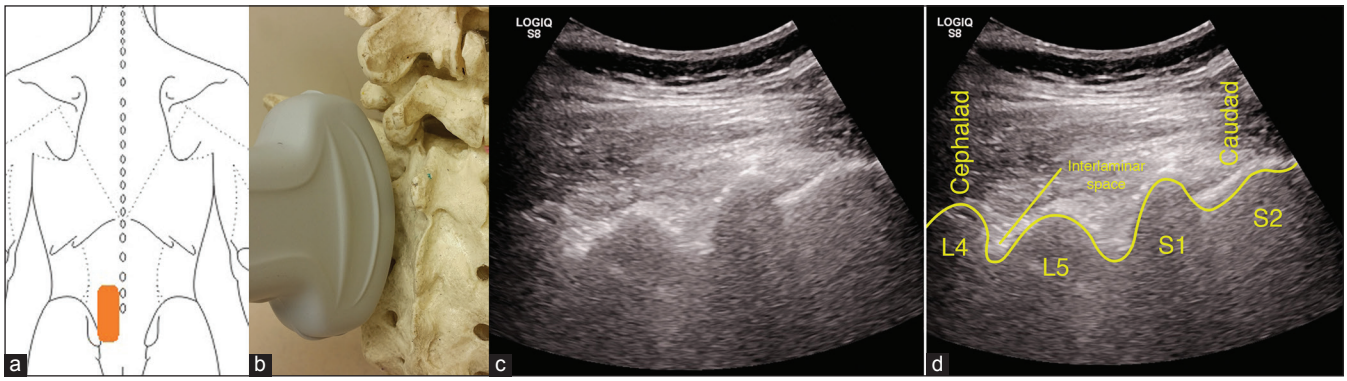

Figure 1: Paramedian sagittal (a and b) view (with median probe orientation) showing classic "saw-tooth" appearance (c and d) representing lamina and interlaminar space

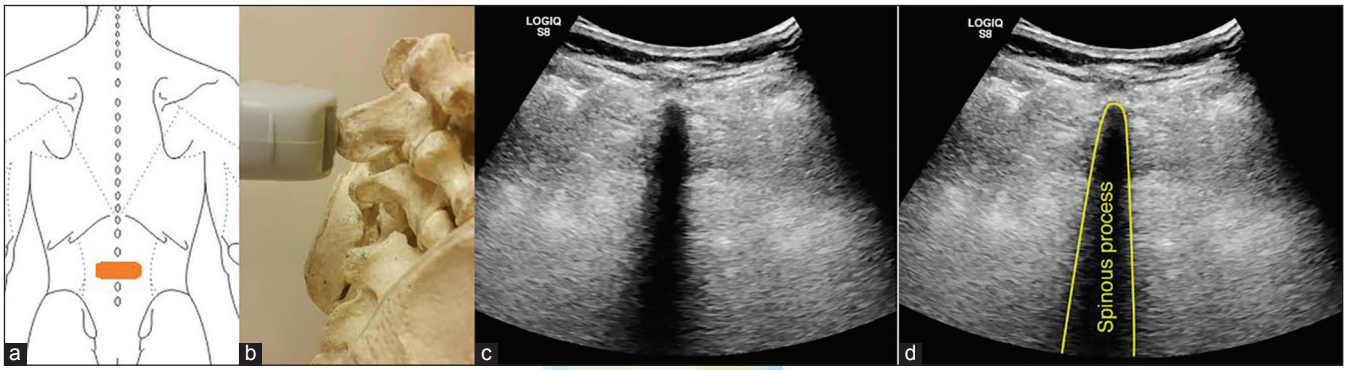

Figure 2: Transverse spinous process (a and b) approach showing "tower" like appearance of the spinous process (c and d)

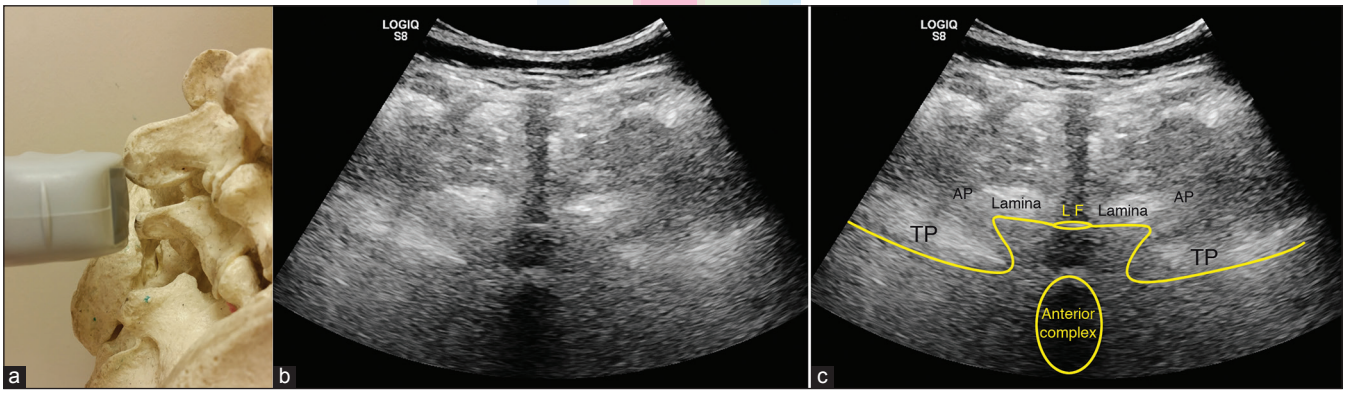

Figure 3: Transverse interspinous (a) view showing "flying bat appearance" (highlighted with yellow line). Posterior dark midline is represented by interspinous ligament. Lamina, articular process and transverse process are seen (b and c). Anterior complex (anterior dura, anterior epidural space, posterior longitudinal ligament, and the posterior aspect of the vertebral body) can be visualized deep to spinal canal (b and c)

course which consists of a mixture of lectures, workshops and plentiful hands-on practice. The use of virtual spine website (http://www.usra.ca/vspine.php) has also shown to improve performance amongst novice anesthesiologists learning this technique.[25] The use of epidural simulator in future may also allow the measurement in real time the depth of needle tip during insertion and interspinous pressure changes through a pressure measurement device as the epidural needle is advanced through the tissue layers.[26]

LIMITATIONS

Currently, there is no evidence-based curriculum available for trainees in UK or novice anesthesiologists. In fact, less than 50% obstetric units have dedicated anesthetic US machine in the UK.[27] Our obstetric unit experience also suggests that despite availability, not all our colleagues use the US routinely. Financial constraint, lack of experience, unavailability of curvilinear probes, difficult real-time visualization of needle and catheter, the urgency of cesarean section and poor evidence

of its benefit pertaining to US of spine are some of the reasons against its routine use.[27]

In addition to the learning curve, time delay is another concern for routine use of US for elective LSCS. Breach *et al.*[28] demonstrated that with adequate preparation and training, the use of US needed only additional 4.5 min for the total set up time of the procedure. However, it reduced around 1 min the time for the actual procedure itself with potential reduction in number of failed procedures, needle passes and traumatic complications. There are no data for use of US during emergency LSCS. Correct identification of landmarks with US does not guarantee successful completion of procedure. When the landmarks are easily palpable, US may not affect time or technical aspects of spinal or epidural procedure.[29] Technology and technique for real-time US-guided spinal and epidural procedures remains elusive at present.

CONCLUSION

We predict US would become increasingly common in identifying the midline (as a minimum) to reduce the number of failed attempts and needle redirections. It has the potential to improve patient safety and satisfaction in subgroup patients with anticipated difficulty in success of neuraxial techniques. In future, with technological advancements real-time US-guided CNBs may be feasible with higher success in anticipated difficult cases.[30] The use of US is a valuable skill for all obstetric anesthesiologists.

Acknowledgment

The images (Figures 1-3) are modified by Dr. Santosh Patel with the help of medical illustrator Mr. Harry Heyes of Central Manchester University Hospitals. The original images are courtesy of 'Ultrasound of the Spine Workshop'.

Jason Lie, Santosh Patel[1]

North Western Deanery, [1]Pennine Acute NHS Trust, The Royal Oldham Hospital, Manchester, United Kingdom

Address for correspondence: Dr. Santosh Patel, Consultant Anaesthetist, Pennine Acute NHS Trust, The Royal Oldham Hospital, Manchester, United Kingdom. E-mail: santosh.patel@pat.nhs.uk

REFERENCES

1. Cook TM, Counsell D, Wildsmith JA; Royal College of Anaesthetists Third National Audit Project. Major complications of central neuraxial block: report on the Third National Audit Project of the Royal College of Anaesthetists. Br J Anaesth 2009;102:179-90.
2. Pan PH, Bogard TD, Owen MD. Incidence and characteristics of failures in obstetric neuraxial analgesia and anesthesia: A retrospective analysis of 19,259 deliveries. Int J Obstet Anesth 2004;13:227-33.
3. Render CA. The reproducibility of the iliac crest as a marker of lumbar spine level. Anaesthesia 1996;51:1070-1.
4. Wong CA, Nathan N, Brown DL. Spinal, epidural, and caudal anesthesia: Anatomy, physiology, and technique. In: Chestnut DH, Polley LS, Tsen LC, Wong CA, editors. Chestnut's Obstetric Anesthesia: Principles and Practice. 4th ed. Philadelphia: Mosby Elsevier; 2009. p. 224.
5. Saifuddin A, Burnett SJ, White J. The variation of position of the conus medullaris in an adult population. A magnetic resonance imaging study. Spine (Phila Pa 1976) 1998;23:1452-6.
6. Reynolds F. Damage to the conus medullaris following spinal anaesthesia. Anaesthesia 2001;56:238-47.
7. Tuominen M, Taivainen T, Rosenberg PH. Spread of spinal anaesthesia with plain 0.5% bupivacaine: Influence of the vertebral interspace used for injection. Br J Anaesth 1989;62:358-61.
8. Lie J, Venkataraju A, Bhatia K, Kochhar P. Audit on the ultrasound analysis of the accuracy of landmark approach to central neuraxial blocks in anaesthesia. Reg Anesth Pain Med 2013;38:64.
9. Broadbent CR, Maxwell WB, Ferrie R, Wilson DJ, Gawne-Cain M, Russell R. Ability of anaesthetists to identify a marked lumbar interspace. Anaesthesia 2000;55:1122-6.
10. Srinivasan KK, Deighan M, Crowley L, McKeating K. Spinal anaesthesia for caesarean section: An ultrasound comparison of two different landmark techniques. Int J Obstet Anesth 2014;23:206-12.
11. Furness G, Reilly MP, Kuchi S. An evaluation of ultrasound imaging for identification of lumbar intervertebral level. Anaesthesia 2002;57:277-80.
12. Lee AJ, Ranasinghe JS, Chehade JM, Arheart K, Saltzman BS, Penning DH, *et al.* Ultrasound assessment of the vertebral level of the intercristal line in pregnancy. Anesth Analg 2011;113:559-64.
13. Lee Y, Tanaka M, Carvalho JC. Sonoanatomy of the lumbar spine in patients with previous unintentional dural punctures during labor epidurals. Reg Anesth Pain Med 2008;33:266-70.
14. Halpern SH, Banerjee A, Stocche R, Glanc P. The use of ultrasound for lumbar spinous process identification: A pilot study. Can J Anaesth 2010;57:817-22.
15. Chin KJ, Perlas A, Chan V, Brown-Shreves D, Koshkin A, Vaishnav V. Ultrasound imaging facilitates spinal anesthesia in adults with difficult surface anatomic landmarks. Anesthesiology 2011;115:94-101.
16. Shaikh F, Brzezinski J, Alexander S, Arzola C, Carvalho JC, Beyene J, *et al.* Ultrasound imaging for lumbar punctures and epidural catheterizations: Systematic review and meta-analysis. BMJ 2013;346:f1720.
17. Perlas A, Chaparro LE, Chin KJ. Lumbar neuraxial ultrasound for spinal and epidural anesthesia: A systematic review and meta-analysis. Reg Anesth Pain Med 2014;ahead of print.
18. Ultrasound-guided cauterization of epidural space. National Institute for Health and Clinical Excellence; January, 2008. https://www.nice.org.uk/guidance/ipg249. [Last accessed on 2015 May 31].
19. Uwubanmwen N and Patel S. A 2 year review of obstetric anesthesia outpatient clinic for high risk obstetric patients. Anesthesiology 2008;109:A1118.
20. Vallejo MC, Phelps AL, Singh S, Orebaugh SL, Sah N. Ultrasound decreases the failed labor epidural rate in resident trainees. Int J Obstet Anesth 2010;19:373-8.
21. Sahin T, Balaban O, Sahin L, Solak M, Toker K. A randomized controlled trial of preinsertion ultrasound guidance for spinal anesthesia in pregnancy: Outcomes among obese and lean parturients: Ultrasound for spinal anesthesia in pregnancy. J Anesth 2014;28:413-9.
22. Rao KP, Russell IF, Purva M. Validation of ultrasound to identify the lumbar intervertebral space in morbidly obese using MRI imaging as the gold standard — A pilot study. Int J Obstet Anesth 2012;21:S10.
23. Brodsky JB, Mariano ER. Regional anaesthesia in the obese patient: Lost landmarks and evolving ultrasound guidance. Best Pract Res Clin Anaesthesiol 2011;25:61-72.
24. Margarido CB, Arzola C, Balki M, Carvalho JC. Anesthesiologists' learning curves for ultrasound assessment of the lumbar spine. Can J

Anaesth 2010;57:120-6.Niazi AU, Tait G, Carvalho JC, Chan VW. The use of an online three-dimensional model improves performance in ultrasound scanning of the spine: A randomized trial. Can J Anaesth 2013;60:458-64.

25. Niazi AU, Tait G, Carvalho JC, Chan VW. The use of an online three-dimensional model improves performance in ultrasound scanning of the spine: A randomized trial. Can J Anaesth 2013;60:458-64.
26. Vaughan N, Dubey VN, Wee MY, Isaacs R. Devices for accurate placement of epidural Tuohy needle for anaesthesia administration. Mech Sci 2014;5:1-6.
27. Clegg I, Bhatia K, Kochhar P, Maguire S. The availability and use of ultrasound in obstetric anaesthesia in the UK. Int J Obstet Anesth 2014;23:S17.
28. Breach H, Muchatuta N. Ultrasound for spinal anaesthesia for elective caesarean section. Int J Obstet Anesth 2014;23:S50.
29. Ansari T, Yousef A, El Gamassy A, Fayez M. Ultrasound-guided spinal anaesthesia in obstetrics: Is there an advantage over the landmark technique in patients with easily palpable spines? Int J Obstet Anesth 2014;23:213-6.
30. Johnson JE, Perlas A, Chin KJ. Ultrasound guidance for central neuraxial anesthesia and Analgesia. Adv Anesth 2014;32:149-69.